

EP CASE REPORT

Fatal aortic dissection associated with catheter ablation

Roberto Keegan^{1*}, Sohaib Haseeb², Leonardo Onetto¹, Franco Gregoriotti¹, and Ricardo Urruti¹

¹Electrophysiology Service, Hospital Privado del Sur, Bahia Blanca, Argentina; and ²Division of Cardiology, Queen's University, Kingston, ON, Canada

* Corresponding author. Tel: +5492914124710. E-mail address: robertokeegan@gmail.com

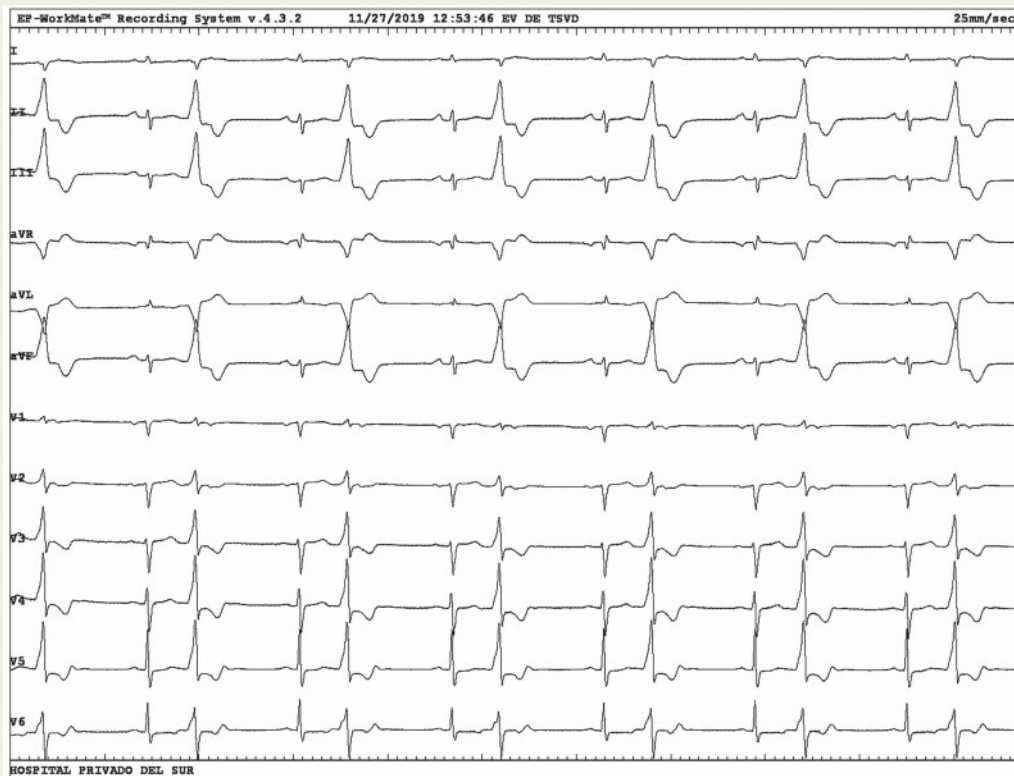


Figure 1 A computed tomography sagittal view showing extensive aortic dissection (ascending and descending) with true and false lumens.

Introduction

Catheter-induced aortic dissection is an infrequent, but potentially severe complication that carries a high risk of morbidity and mortality. Type A and Type B non-fatal aortic dissection related to ablation of left ventricular (LV) arrhythmias have been reported.^{1,2} Most of these cases are promptly identified and treated. However, there is little information about extensive and life-threatening aortic dissection.

Case report

A 73-year-old woman with LV non-compaction cardiomyopathy, severely depressed LV systolic function (ejection fraction of 28%), and a high burden (31%) of monomorphic premature ventricular complexes was referred for catheter ablation under conscious sedation. Because of suspected LV summit origin, retrograde access was established ([Supplementary material](#) online). A short sheath (8-Fr × 11 cm), which was subsequently exchanged for a long one (8.5-Fr × 63 cm), was introduced through the right femoral artery and a 4-mm-tip irrigated ablation catheter (FlexAbility™, Abbott, Chicago, IL, USA) was easily advanced into the aorta and the left ventricle. Although the patient had complained of slight lower back pain before the exchange of sheaths, no warning signs of a traumatic arterial dissection were noticed. During mapping of the left coronary cusp and the LV outflow tract, a sudden severe pericardial effusion was detected. Following pericardiocentesis, a dissection flap at the aortic arch was observed by intracardiac echocardiography ([Supplementary material](#) online,

Video S1). Urgent computed tomography (CT) revealed an extensive aortic dissection spreading to the brachiocephalic trunk and the right carotid and left iliac arteries (Figure 1). The patient was rushed for an extensive surgical repair (aortic valve resuspension, ascending aortic replacement, descending aorta grafting, and femoral–femoral bypass). A refractory shock associated with clinical findings of mesenteric ischaemia led to the patient's death within the first 24 h after surgery.

Discussion

Fatal aortic dissection complicating catheter ablation is extremely rare. Nevertheless, there is one reported case of fatal aortic and coronary dissection during left-sided ablation using a 4-mm solid-tip catheter, presumably due to catheter-induced trauma.³ In our case, because the tear was not found at the ascending aorta, the mechanism of dissection may be a tear at a lower level of the aorta or in the right iliac artery, or an aortic haematoma. Although aortic atheromas were previously ruled-out by a preoperative CT scan, we had noticed an unusual and fast evolution of the dissection. Although typical clinical findings of Marfan syndrome were not present, a predisposition to dissection cannot be excluded because of the observation of a friable media layer of all arteries during surgery.

Operators should consider aortic dissection as a possible cause of tamponade and death during catheter ablation. Transseptal access should be considered as the first choice in elderly patients, even in the absence of any suspected predisposing factors for arterial dissection.

Supplementary material

Supplementary material is available at *Europace* online.

Conflict of interest: none declared.

References

1. Kuroki K, Sato A, Yamagami F, Nogami A, Aonuma K. Life-threatening aortic dissection with cardiac tamponade during catheter ablation for ventricular tachycardia originating from left coronary cusp. *J Cardiovasc Electrophysiol* 2017;**28**:1224–5.
2. Yeshwant SC, Tsai MH, Jones BR, Hamlin MP, Bensimhon AD, Lustgarten DL. Iatrogenic type A aortic dissection during idiopathic ventricular tachycardia ablation. *Heart Rhythm Case Rep* 2017;**3**:396–9.
3. Janeira LF. Coronary artery dissection complicating radiofrequency catheter ablation via the retrograde approach. *Pacing Clin Electrophysiol* 1998;**21**:1327–8.